

# Endoscopically Assisted Decompression for Pronator Syndrome

Andrew K. Lee, MD, Mark Khorsandi, DO, Nurulhusein Nurbhai, DO, Joseph Dang, MD, Michael Fitzmaurice, MD, Kyle A. Herron, MD

**Purpose** Traditional surgical management for pronator syndrome results in a relatively long and possibly disfiguring scar across the antecubital fossa. The purposes of this study were to present an endoscopic technique that facilitates the decompression of the proximal median nerve without extensile incisions, and to evaluate whether this minimally invasive procedure could adequately and safely treat the condition to improve outcome scores.

**Methods** We treated 13 patients (14 cases) with isolated pronator syndrome with endoscopically assisted decompression and retrospectively reviewed them. We excluded patients with concomitant carpal tunnel syndrome or other compression neuropathies. The average age of the patient at presentation was 41 years. Final follow-up averaged 22 months. We asked all patients to rate their preoperative and postoperative condition and functional capabilities using the validated Disabilities of the Shoulder, Arm, and Hand (DASH) scoring protocol.

**Results** All 13 patients improved symptomatically as reflected in the DASH score assessment. The preoperative scores averaged 56 and the postoperative scores were significantly reduced and averaged 6. There were 3 minor complications, which resolved spontaneously.

**Conclusions** The endoscopically assisted, minimally invasive approach to treat pronator syndrome adequately and safely decompressed all anatomical points of compression and improved DASH scores. This may reduce morbidity and facilitate a quicker recovery compared with the traditional open incision techniques. (*J Hand Surg* 2012;37A:1173–1179. Copyright © 2012 by the American Society for Surgery of the Hand. All rights reserved.)

**Type of study/level of evidence** Therapeutic IV.

**Key words** Pronator syndrome, endoscopic decompression, technique, outcome.

**P**RONATOR SYNDROME (PS), or proximal forearm median nerve compression neuropathy, can often be overlooked and inadequately diagnosed. Initially described in 1951,<sup>1</sup> it is a constellation of symptoms in-

cluding aching pain in the volar forearm, and it is associated with paresthesias in the median nerve (MN) distribution.<sup>2,3</sup> Other symptoms include weakness with grip.<sup>3</sup> It is often difficult to distinguish PS from carpal tunnel syndrome (CTS) because the presentations can be similar and there are few physical findings that are sensitive and specific for PS.<sup>4–6</sup> The 5 common sites of compression from proximal to distal include the ligament of Struthers, the lacertus fibrosus, vascular leashes across the nerve, the fibrous band of pronator teres (PT) muscle, and the fibrous arch of the flexor digitorum superficialis (FDS) muscle.<sup>5</sup> There have been several descriptions of the surgical approach for decompression of the nerve in this region, including a lazy S incision, modified lazy S incision with 2 offset linear incisions,<sup>7</sup> and a transverse incision.<sup>8</sup> Most incisions begin at least 5 cm proximal to the elbow and

From the Department of Orthopedic and Hand Surgery, American Total Orthopedics/Brown Hand Center, Houston, TX.

Received for publication January 14, 2011; accepted in revised form February 14, 2012.

The authors thank Michael G. Brown, MD, Randolph Lopez, MD, Robert D. Harper, MD, and Jackson Ombaba, MD, for valuable input.

No benefits in any form have been received or will be received related directly or indirectly to the subject of this article.

**Corresponding author:** Andrew K. Lee, MD, Department of Orthopedic Surgery, American Total Orthopedics/Brown Hand Center, 915 Gessner Road, Ste. 975, Houston, TX 77024; e-mail: alee@thehandcenter.com.

0363-5023/12/37A06-0010\$36.00/0  
doi:10.1016/j.jhssa.2012.02.023

**TABLE 1. Patient Demographics**

Patient	Age	Sex	Hand Dominance	Affected Side	Duration of Symptoms Before Diagnosis (mo)	Duration of Nonoperative Treatment (mo)	Nonoperative Treatment	Medical Comorbidities	Associated Diagnosis
1	40	F	R	L	1	5	NSAIDs, AM, MDP		DQ, TF
2	43	F	R	R	2	6	NSAIDs, AM		DQ
3	47	F	R	R	1	4	NSAIDs, AM, SP	DM, HT	
4	25	F	R	R	2	3	NSAIDs, AM, SP, MDP		
5	34	F	R	L	2	6	NSAIDs, AM, SP		
6	23	F	R	R	1	6	NSAIDs, AM, SP		
7	46	F	R	B	4	3	NSAIDs, AM, SP, MDP	RA	
8	36	F	R	L	3	5	NSAIDs, AM, SP		
9	48	F	L	L	6	4	NSAIDs, AM, SP	HT	
10	40	F	L	R	3	5	NSAIDs, AM, SP, MDP		
11	68	F	R	L	1	8	NSAIDs, AM, SP	CAD, DM	TF
12	52	F	R	L	6	5	NSAIDs, AM, SP	DM	DQ
13	36	F	R	R	2	6	NSAIDs, AM, SP, MDP		

NSAIDs, nonsteroidal anti-inflammatory drugs; AM, activity modification; SP, splinting; MDP, Medrol dose-pak (methylprednisolone; Pfizer, Inc., New York, NY); DM, diabetes mellitus; HT, hypothyroidism; RA, rheumatoid arthritis; CAD, coronary artery disease; DQ, de Quervain tenosynovitis; TF, trigger finger.

extend distally across the cubital fossa to the mid-forearm level.<sup>9</sup> The relatively long scar across the cubital fossa resulting from these incisions can be disfiguring.<sup>7</sup> Endoscopically assisted pronator release (EAPR) eliminates the need for these extensile incisions but permits decompression of all anatomical points of compression.

The purposes of this study were to present an endoscopic technique that can facilitate the decompression of the proximal MN without extensile incisions, and to assess whether this approach can also adequately and safely treat PS and improve outcome scores.

## MATERIALS AND METHODS

### Patient characteristics

We conducted a retrospective case review of patients who were diagnosed with PS and who had undergone EAPR by one of 5 surgeons at our center from April 2008 to May 2010. We excluded patients with concomitant cervical radiculopathy, thoracic outlet syndrome, peripheral neuropathies, history of spine or brain injury or stroke, and history of severe trauma or previous operations on the affected extremity. Other exclusion criteria included patients with concomitant CTS or other compression

neuropathies. No patients were receiving workers' compensation.

We included 13 patients with PS (6 right-sided, 6 left-sided, and 1 bilateral) (Table 1). The average age at presentation was 41 years (range, 24–67 y). We noted systemic disorders (diabetes mellitus, hypothyroidism, coronary artery disease, and rheumatoid arthritis) in 5 patients (38%). All patients had paresthesias in the MN distribution, proximal forearm pain, and reproduction of the symptoms with a positive pronator compression test.<sup>10</sup> Of the 13 patients, 6 had positive provocative tests, 6 had a positive Tinel sign in the proximal forearm, and 10 had forearm tenderness. No patients had evidence of a supracondylar process on the radiographs. Electrodiagnostic testing was positive for PS in all patients. Each patient had a minimum of at least 3 months of conservative treatment (activity modification, splinting, anti-inflammatory medications, or oral steroids) without improvement. None had prior corticosteroid injections. The average duration of nonoperative treatment was 5 months (range, 3–8 mo) (Table 1). We offered all 13 patients the option of traditional open versus EAPR to treat the PS, and all chose to undergo EAPR.

Concomitant diagnoses such as de Quervain tenosynovitis and trigger finger were treated at the same surgical setting (Table 1). All 5 surgeons were experienced in endoscopic techniques of carpal tunnel release and cubital tunnel release. All patients were asked to rate their preoperative and postoperative condition and functional capabilities using the validated Disabilities of the Arm, Shoulder, and Hand (DASH) scoring protocol. We obtained both preoperative and postoperative DASH scores retrospectively; the DASH scores on 8 patients were obtained during their clinic visits, and on 5 were obtained through telephone interviews. All patients were physically examined preoperatively and postoperatively during clinic visits by one of the authors. We obtained institutional review board approval.

### Electrodiagnostic study

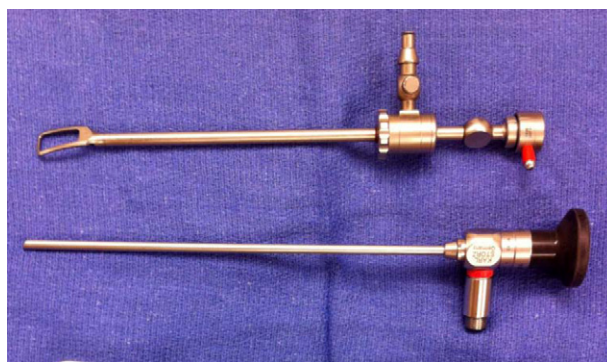
Before surgical release of PS, all patients underwent electrodiagnostic evaluations performed by a board-certified physiatrist. All responses were recorded on a NeuroMax model 1002 electromyography (EMG) machine (XLTEK.com, Oakville, Ontario, Canada). We maintained the extremity temperature at 32°C to 34°C and checked it periodically during the study with a skin surface thermometer (Dermatemp; Exergen, Wauertown, MA).

A nerve conduction study preceded a needle EMG. To rule out CTS, we performed a standard carpal tunnel conduction study on all patients. Patients who had clinical symptoms in both the hand and forearm coupled with a normal carpal tunnel study raised the index of suspicion for PS. We then performed EMG to rule out cervical radiculopathy and to evaluate for PS. We considered EMG abnormalities limited to 2 median innervated muscles of the forearm distal to the PT to be diagnostic for PS.<sup>11</sup>

### Operative technique

The patient is placed in a supine position and the tourniquet is placed as proximally as possible and inflated.

A 3-cm incision is made 3 to 4 cm distal to the cubital crease over the palpable radial border of the flexor mass, slightly ulnar to the midline extending distalward. We prefer a longitudinal incision in case it becomes necessary to convert to an extensile exposure. Subcutaneous tissues are divided, taking care to protect and preserve sensory nerve branches and control bleeders with a bipolar cautery. The basilic vein is identified and retracted, and the lacertus fibrosus is identified and divided completely under direct vision as the MN is close by. The PT muscle mass is retracted medially, and

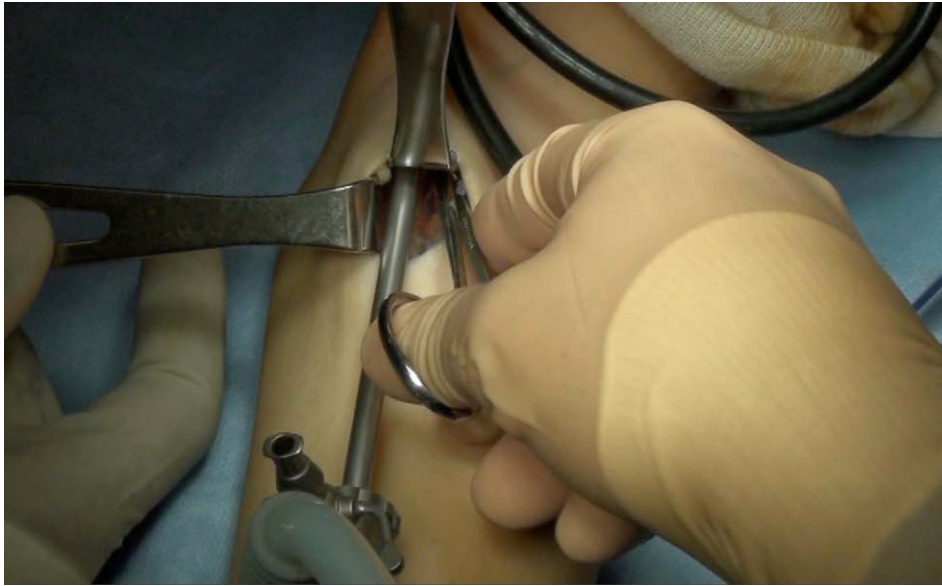

**FIGURE 1:** Hoffmann endoscopic sheath and 4.0-mm endoscope.

the biceps and brachioradialis are retracted laterally. Blunt dissection is carried out to reveal the MN, which is located medial and deep to the brachial artery. The nerve is dissected as distally and proximally as direct vision allows until a plane is developed for the insertion of the endoscope. Restrictive vascular arcades, if encountered, are carefully released and proper hemostasis is achieved with a bipolar cautery.

The Hoffmann scope (Karl Storz, Tuttlingen, Germany) has a specialized tip that allows for blunt dissection between the muscles and fascial planes and lifts up the overlying soft tissue to allow visualization of structures below (Fig. 1). It is helpful to keep the endoscope and instruments warm before the procedure to prevent fogging of the lens. The endoscope is then inserted in the proximal direction, lifting the soft tissues above the MN. We have found a Freer elevator to be helpful in retracting the soft tissues for better visualization. Deep retractors are also useful. Using scissors, the proximal extension of the bicipital aponeurosis is then carefully released under endoscopic view. The blunt tip of the endoscopic sheath is used to gently lift the soft tissues above the nerve. At no time should the scissors be closed without thorough visualization through the scope. Complete release of the constricting fascia over the MN and the ligament of Struthers, if present, is achieved. Insertion of the small finger ensures that the constricting fascia is completely released.

The endoscope is then directed distally. The tendinous or fibrous bands within the PT muscle are identified under endoscopic view. Using scissors, careful dissection of the MN is achieved by the spreading and cutting technique (Fig. 2). Often, the deep head of the PT has a fibrous portion that puts pressure on the median or anterior interosseous nerve (AIN). Using the scissors, the fibrous band is released. The constricting ulnar and humeral head of the PT muscle can also



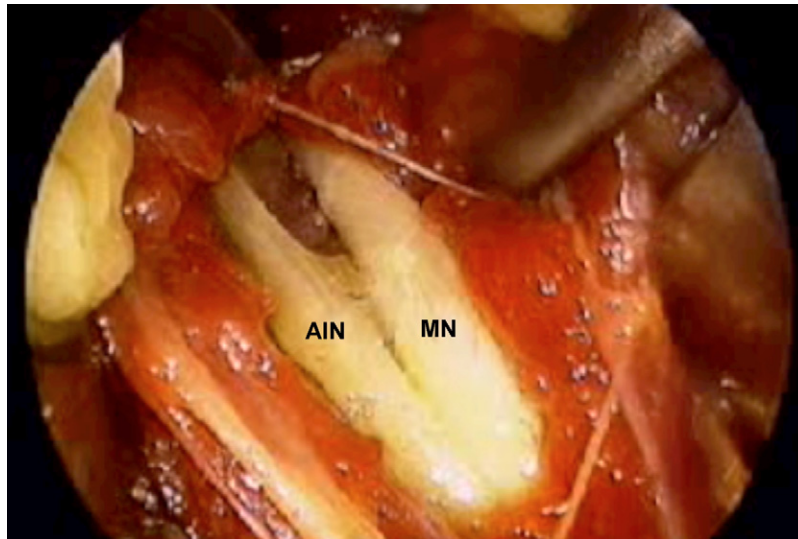
**FIGURE 2:** Using scissors, careful dissection of the median nerve is achieved by the spreading and cutting technique under the endoscopic view. Deep retractors are useful in retracting soft tissue structure to help visualize the median nerve.

**FIGURE 3:** Careful endoscopic dissection reveals the fibrous arch (FA) of the flexor digitorum superficialis where the compression of the median nerve (MN) is often encountered.

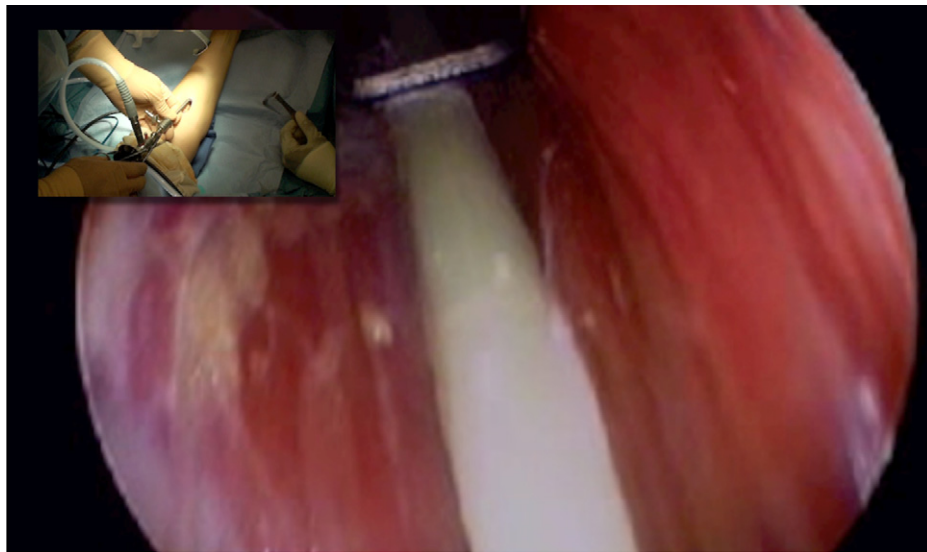
be released by the spreading and cutting technique; however, the nerve should always be visible through the endoscope before making any cuts. The dissection is then carefully carried to the fibrous arch of the FDS, where the nerve compression is frequently encountered (Fig. 3). The arch is identified and released using scissors. The decompression of the MN and the AIN distal to the arch is confirmed (Fig. 4). The small motor branches of the AIN and the continuation of the MN past the FDS muscle distally are confirmed (Fig. 5).

The endoscope is removed and the tourniquet is deflated. Hemostasis can be achieved with a bipolar cautery when necessary. After 7 to 10 days, gentle range of motion and light lifting activities can begin, and heavy lifting activity follows in several weeks as tolerated.

Our indications for converting to an open procedure are the inability to adequately visualize the MN owing to equipment issues or anatomical variations, the inability to achieve complete decompression of the nerve owing to technical difficulties, and unsuccessful hemostasis. Relative contraindications to EAPR are an acute



**FIGURE 4:** Upon complete release of the fibrous arch of FDS, the median nerve (MN) and the anterior interosseous nerve (AIN) branch can be seen through the endoscopic view.



**FIGURE 5:** Complete decompression along the full course of the median nerve is confirmed.

traumatic setting and previous forearm surgery or injury that may have resulted in extensive adhesions or distorted anatomy.

#### Statistical analysis

We compared postoperative DASH scores with preoperative scores using Student's paired *t*-test. Statistical significance was accepted for a *P* value less than .05.

#### RESULTS

All patients underwent EAPR without conversion to an open procedure. Intraoperatively, 9 patients had com-

pression from fascial bands of PT, and 4 had compression at the level of fibrous arch of FDS. We noted no noteworthy compression at the level of lacertus fibrosus or vascular leashes, and no patients had evidence of a ligament of Struthers.

Duration of follow-up averaged 22 months (range, 11–37 mo). All 13 patients noted symptomatic improvement and on DASH score assessment. Preoperative DASH scores averaged 57 (range, 18–82) and postoperative DASH scores averaged 6 (range, 0–21). We noted average improvement in DASH score to be 51 points, which is 90% improvement from the preop-

**TABLE 2. Outcome of Endoscopically Assisted Decompression of Pronator Syndrome**

Patient	Follow-up Duration (mo)	Residual Paresthesias (Time to Recovery [wk])	Residual Pain (Time to Recovery [wk])	Scar Tenderness (Time to Recovery [wk])	Preoperative DASH Score	Postoperative DASH Score	Complications
1	24	– (1)	– (1)	– (8)	64	9	None
2	22	– (4)	– (8)	– (8)	76	0	None
3	37	– (1)	+	– (12)	18	15	None
4	36	– (1)	+	+	37	16	None
5	30	– (1)	– (1)	– (4)	47	0	None
6	25	– (1)	– (1)	– (8)	31	9	None
7	19	– (1)	– (8)	– (8)	68	0	Transient AIN palsy
8	35	– (8)	– (8)	– (8)	63	0	Hematoma
9	13	– (4)	– (12)	– (12)	81	0	None
10	14	– (1)	– (1)	– (4)	37	0	None
11	11	– (4)	– (8)	– (8)	82	1	None
12	12	– (1)	+	– (12)	61	21	Allergic reaction to adhesive
13	12	– (4)	– (4)	– (8)	71	2	None

erative average DASH score ( $P < .05$ ). Of the 13 patients, 6 had a DASH score of 0 at most recent follow-up.

Postoperatively, we examined the patients at 1 week and then monthly thereafter for 3 months for residual paresthesias, residual forearm pain, and scar tenderness (Table 2). All patients reported resolution of paresthesias. Scar tenderness was resolved within 12 weeks in 12 patients, and 1 patient had mild, unresolved scar tenderness. Three patients had mild residual forearm pain with vigorous activity. Minor transient complications occurred in 3 patients. One patient had an AIN palsy that had resolved at 4 weeks, 1 had a hematoma that resolved by 3 weeks, and 1 had an allergic reaction from adhesive dressing that was treated with oral steroids and antihistamine medication.

All patients said they were glad they had the procedure done and were satisfied with the scar appearance. Twelve said they would have the surgery again if needed. One patient noted uncertainty in having the surgery again because there was only partial relief of symptoms.

## DISCUSSION

Seyffarth<sup>1</sup> described PS in 1951, and Johnson et al<sup>10</sup> described the pathology based on their surgical decompression of the MN. Compression of the MN in the forearm can occur both proximal and distal to the an-

tecubital fossa. The most proximal site of MN compression involves the ligament of Struthers, with or without an associated supracondylar process.<sup>12</sup> A distal accessory bicipital aponeurosis was also described as a specific cause of anterior interosseous palsy.<sup>13</sup> Most cases in the literature reported fibrous bands at the level of the 2 heads of the PT muscle as the most common site of compression of MN.<sup>14–16</sup> In our series, we observed compression at this location in 9 of 13 patients. Other potential sites of compression include the bicipital aponeurosis, the FDS arch, an accessory or anomalous Gantzer muscle (accessory head of flexor pollicis longus), palmaris profundus, flexor carpi radialis brevis, and enlarged communicating veins.<sup>17,18</sup> Traumatic etiologies include forearm fractures and supracondylar humerus fractures.<sup>19</sup> Direct trauma from penetrating wounds and external compression, such as from airbag deployment injuries, can also result in proximal MN compression; however, we do not advocate EAPR in these acute traumatic settings.

With the advent of endoscopic interventions to treat compressive neuropathies and the success of both endoscopic carpal tunnel and cubital tunnel releases,<sup>20–22</sup> we were spurred to evaluate the application of endoscopic technique to decompress the MN proximally. Historically, the operative technique for proximal MN compression involved extensile exposures. Fearn and Goodfellow<sup>23</sup> described a longitudinal incision over the

anterior forearm, and Johnson et al<sup>10</sup> recommended a volar zigzag approach starting at the medial aspect of the antecubital crease, progressing across the anterior forearm. Tsai and Syed<sup>8</sup> reported on a transverse proximal forearm incision affording adequate exposure; nevertheless, it still requires an 8-cm incision. The EAPR eliminates the need for these long incisions, because we have been able to achieve a complete release of all potential sites of compression with a 3-cm incision.

Several authors have reported improved outcomes with surgical decompression of the proximal MN. Johnson et al<sup>10</sup> reported good results in 47 of 51 patients who had undergone surgical decompression, Hartz et al<sup>3</sup> in 33 of 36 patients, Stal et al<sup>24</sup> in 12 of 14 patients, Olehnik et al<sup>25</sup> in 30 of 39 patients, and Werner et al<sup>26</sup> in 8 of 9 patients. Although previously reported studies used different means of evaluation, a reasonable outcome comparison can be made with these historical controls. Our results, which were based on the DASH score, showed that all patients improved, with an average score difference of 51 points. Of 13 (62%) patients, 8 had complete or near complete resolution of symptoms, 2 had clearly improved symptoms with only occasional mild symptoms, and 3 had improved but partial relief of symptoms. Although these 3 patients' postoperative DASH scores were greater than 10, all of their scores improved after surgery. All 3 had residual forearm discomfort, and 1 had scar tenderness.

Endoscopic surgery has the potential advantage of providing good or better visualization with a smaller skin incision, and less postoperative pain. One limitation of this study is the lack of a control group with the standard open approach. Our belief that recovery is quicker with less postoperative pain and scarring has, therefore, not been definitively demonstrated. Another limitation of this study is the small patient group, which can be explained by a relatively lower prevalence of this condition in the general population compared with other compression neuropathies, and the fact that many patients also have concomitant CTS or double crush syndrome, which we excluded from this study. Our study is also limited in that we did not exclude patients with concomitant conditions such as de Quervain disease or trigger finger, because their symptoms were different from PS. Treatment of these conditions at the same time may have had an influence on the postoperative DASH scores. The preoperative DASH scores obtained retrospectively may also have influenced the accuracy of the data.

Prospective, randomized, controlled studies with long-term follow-up are needed to support these findings of success with endoscopic release for PS.

## REFERENCES

- Seyffarth H. Primary myositis in the M. pronator teres as cause of lesion of the N. medianus (the pronator syndrome). *Acta Psychiatr Neurol Scand Suppl* 1951;74:251-254.
- Eversmann WW. Proximal median nerve compression. *Hand Clin* 1992;8:307-315.
- Hartz CR, Linscheid RD, Gramse RR, Daube JR. The pronator teres syndrome: compressive neuropathy of the median nerve. *J Bone Joint Surg* 1981;63A:885-890.
- Lee MJ, LaStayo PC. Pronator syndrome and other nerve compressions that mimic carpal tunnel syndrome. *J Orthop Sports Phys Ther* 2004;34:601-609.
- Rehak D. Pronator syndrome. *Clin Sports Med* 2001;20:531-540.
- Tsai P, Steinbrer DR. Median and radial nerve compression about the elbow. *Instr Course Lect* 2008;57:177-185.
- Gainor BJ. Modified exposure for pronator syndrome decompression: a preliminary experience. *Orthopedics* 1993;16:1329-1331.
- Tsai TM, Syed SA. A transverse skin incision approach for decompression of pronator teres syndrome. *J Hand Surg* 1994;19B:40-42.
- Szabo RM. Median nerve release: proximal forearm. In: Blair WF, ed. *Techniques in hand surgery*. Baltimore: Williams and Wilkins, 1996:754-764.
- Johnson RK, Spinner M, Shrewsbury MM. Median nerve entrapment syndrome in the proximal forearm. *J Hand Surg* 1979;4:48-51.
- Gross PT, Jones HR Jr. Proximal median neuropathies: electromyographic and clinical correlation. *Muscle Nerve* 1992;15:390-395.
- Crotti FM, Mangiagalli EP, Rampini P. Supracondyloid process and anomalous insertion of pronator teres as source of median nerve neuralgia. *J Neurosurg Sci* 1981;25:41-44.
- Spinner M. The anterior interosseous-nerve syndrome: with special attention to its variations. *J Bone Joint Surg* 1970;52A:84-94.
- Johnson RK, Spinner M. Median nerve compression in the forearm: the pronator tunnel syndrome. In: Szabo RM, ed. *Nerve compression syndromes: diagnosis and treatment*. Thorofare, NJ: Slack, 1989: 137-151.
- Megele R. Anterior interosseous nerve syndrome with atypical nerve course in relation to the pronator teres. *Acta Neurochir (Wien)* 1988;91:144-146.
- Nigst H, Dick W. Syndromes of compression of the median nerve in the proximal forearm (pronator teres syndrome; anterior interosseous nerve syndrome). *Arch Orthop Trauma Surg* 1979;93:307-312.
- Spinner M, Carmichael SW, Spinner M. Partial median nerve entrapment in the distal arm because of an accessory bicipital aponeurosis. *J Hand Surg* 1991;16A:236-244.
- Braun RM, Spinner RJ. Spontaneous bilateral median nerve compressions in the distal arm. *J Hand Surg* 1991;16A:244-247.
- Geissler WB, Fernandez DL, Graca R. Anterior interosseous nerve palsy complicating a forearm fracture in a child. *J Hand Surg* 1990;15A:44-47.
- Hankins CL, Brown MG, Lopez RA, Lee AK, Dang J, Harper RD. A 12-year experience using the Brown two-portal endoscopic procedure of transverse carpal ligament release in 14,722 patients. *Plast Reconstr Surg* 2007;12:1911-1921.
- Ahcan U, Zorman P. Endoscopic decompression of the ulnar nerve at the elbow. *J Hand Surg* 2007;10A:1171-1176.
- Hoffmann R, Siemionow M. The endoscopic management of cubital tunnel syndrome. *J Hand Surg* 2006;31B:23-29.
- Fearn CBD, Goodfellow JW. Anterior interosseous nerve palsy. *J Bone Joint Surg* 1965;47B:91-93.
- Stal M, Hagert CG, Englund JE. Pronator syndrome: a retrospective study of median nerve entrapment at the elbow in female machine milkers. *J Agric Saf Health* 2004;10:247-256.
- Olehnik WK, Manske PR, Szerzinski J. Median nerve compression in the proximal forearm. *J Hand Surg* 1994;19A:121-126.
- Werner CO, Rosen I, Thorgren KG. Clinical and neurophysiological characteristics of the pronator syndrome. *Clin Orthop Relat Res* 1985;197:231-236.